


CASE REPORT

Negative pressure wound therapy of *Corynebacterium jeikeium* associated granulomatous mastitis

Robert Maráz MD, PhD¹  | László Venczel MD¹ | László Sikorszki MD, PhD¹ |
Orsolya Serfőző MD² | Éva Ambrózay MD² | Márta Patyi MD, PhD³ |
Gábor Cserni MD, PhD^{4,5}

¹Department of Surgery, Bács-Kiskun County Hospital, Kecskemét, Hungary

²MaMMa Clinic, Kecskemét, Hungary

³Department of Infectology, Bács-Kiskun County Hospital, Kecskemét, Hungary

⁴Department of Pathology, Bács-Kiskun County Hospital, Kecskemét, Hungary

⁵Department of Pathology, University of Szeged, Szeged, Hungary

Correspondence

Robert Maráz, Department of Surgery, County Hospital, Kecskemét, Nyíri ut 38, 6000 Kecskemét, Hungary.
Email: marazrobert2010@gmail.com

Abstract

We present the first *Corynebacterium* associated therapy resistant granulomatous mastitis successfully treated with negative pressure wound therapy (NPWT). Our patient had received five different courses of antibiotic therapy, and three surgical explorations before NPWT was introduced and resulted in healing. For a successful treatment, the use of targeted antibiotic therapy, steroid therapy and in case of progressive disease, wide excision is required. When this results in a large wound cavity, NPWT seems an effective and innovative option.

KEYWORDS

Corynebacterium, granulomatous mastitis, negative pressure wound therapy

1 | INTRODUCTION

Mastitis is often divided into lactational and nonlactational types. Common forms of nonlactational mastitis include periductal mastitis and idiopathic granulomatous mastitis (IGM), although this latter is also more common in the peripartum period. Granulomatous mastitis (GM) is a rare form of inflammatory breast disease. Possible etiologies include mammary tuberculosis, other infections, autoimmune mechanisms, and hypersensitivity reactions.

2 | CASE REPORT

A 32-year-old woman was first seen as outpatient with symptoms of right breast pain, erythema, and swelling in June 2017. Mammography and core biopsy were performed and confirmed an inflammatory disease of the breast, with no granulomatous component, but many eosinophils, fewer neutrophils, and a single histiocytic giant cell. The patient empirically received amoxicillin/clavulanic acid, followed by cefuroxime. After a temporary remission of a month, an abscess appeared in the breast. Abscess drainage was performed and a bacterial smear was taken. The microbiological analysis resulted in

coagulase-negative staphylococci and *Corynebacterium jeikeium*, both sensitive to vancomycin, which the patient received for 10 days. A second exploration was needed 2 months later, when two samples were taken for microbiological analysis, resulting in *Staphylococcus epidermidis*, so the patient received clindamycine. One month later, an abscess drainage and bacterial smear were repeated and specimens were excised for histology. The wound culture had *Corynebacterium jeikeium*, and the histology demonstrated GM with lipophilic microcysts. (Figure 1).

In September 2017, the patient had a large wound surface without healing tendency due to prolonged infection, we considered debridement necessary. We decided to use negative pressure wound therapy (NPWT), which is useful in many different types and sizes of wounds,¹ and has been shown to have beneficial effects on wound healing. The Renasys-GO™ (Smith & Nephew Inc Canada) system was used to apply NPWT after a rigorous debridement under general anesthesia (Figures 2 and 3). The initial continuous negative pressure of -90 mm Hg was increased to -120 mm Hg. The foam dressing was changed every 3-5 days, and a good granulation tissue formation was observed. After the first week of NPWT, the wound cavity decreased significantly in volume. The patient received linezolid as targeted antimicrobial therapy in addition to steroids. After 4 weeks,

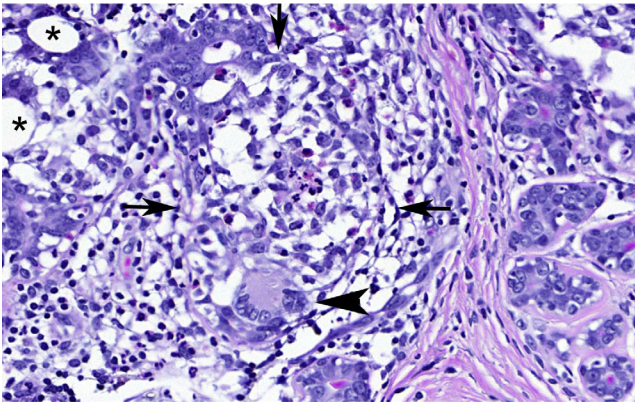


FIGURE 1 A lobulocentric granuloma (arrows) featuring a Langhans-type giant cell (arrowhead). A few neutrophils are seen in the center of the granuloma. The asterisks label microcysts, which atypically do not contain neutrophils in this case, as described in cystic neutrophilic GM²

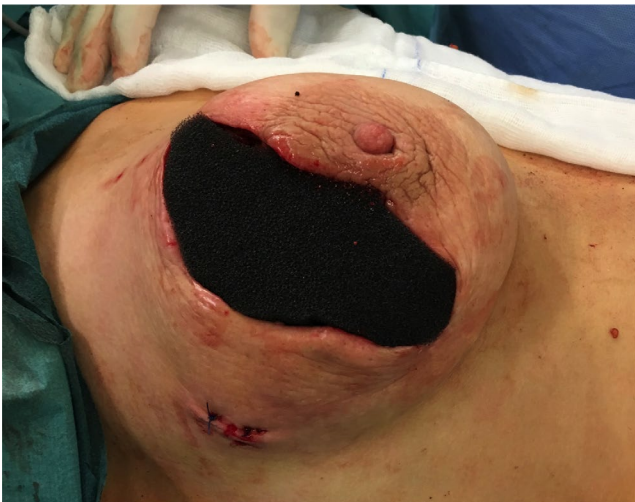

FIGURE 2 Right breast after the excision of the granulomatous tissue, and the cavity containing the tailored foam dressing of the NPWT kit

we completed the NPWT and a secondary closure of the wound was performed. The patient was cured 6 months after first presentation. The initially seemingly intractable disease necessitated a large incision and cavity with the addition of NPWT to evacuate the purulent exudate; consequently, the scar was also large and resulted in no excellent but moderate-to-good cosmetic result (Figure 4). The patient was satisfied with this and declined any second step correction.

3 | DISCUSSION

GM can present a clinical dilemma from diagnostic and therapeutic perspectives. There is increasing evidence of an association between *Corynebacteria* and a distinct pattern termed cystic neutrophilic GM.²⁻⁴ When none of the known etiologies can be proven, the

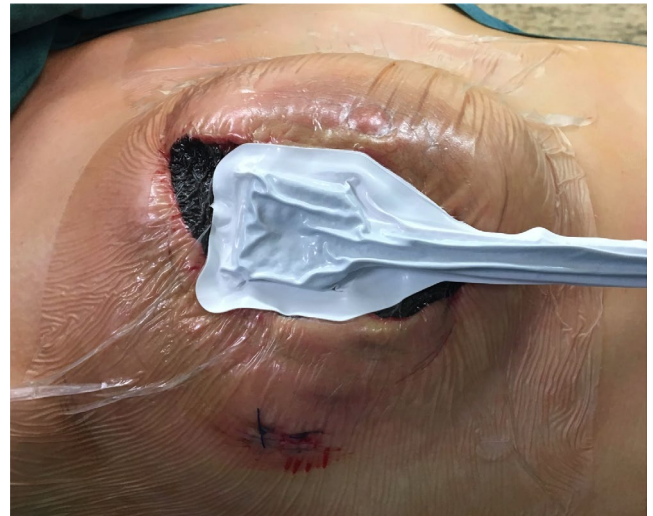

FIGURE 3 Foam dressing in the wound covered by the adhesive film and the suction port applied

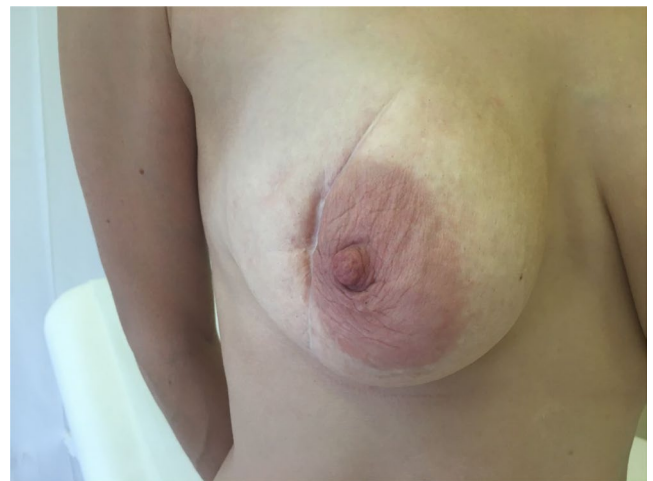

FIGURE 4 Cosmetic result 20 mo after the end of NPWT

disease is labeled as IGM. As the possibility of a *Corynebacterium* infection was often uninvestigated previously, there are cases erroneously classified as IGM. The distinct histological features of granulomatous inflammation with neutrophils in cystic spaces should prompt careful search for rare Gram-positive bacilli. Microbiological investigation for *Corynebacteria* should be instigated in the presence of these histological features. This may require special culture techniques.^{2,3} GM caused by a *Corynebacterium* is often resistant to common initial antibiotic therapy and responds to tetracycline to which this strain was resistant. Sometimes, only targeted antibiotic treatment can be successful with additional surgical excision eliminating necrotic tissue favoring persistent infection. Extensive surgery is limited by esthetic problems. NPWT is nowadays widely used to treat acute, subacute, and chronically infected wounds. The negative pressure generated by the closed system removes

infectious debris and exudates, reduces edema, increases blood flow and neovascularization helping new granulation tissue development and decreases bacterial colonization of wounds.^{5,6} To our knowledge, we present the first successful NPWT assisted treatment of Corynebacterium related therapy resistant GM. In our case, more radical surgery could be avoided by combined antibiotic + steroid + innovative surgical therapies (NPWT).

ORCID

Robert Maráz  <https://orcid.org/0000-0003-0146-6024>

REFERENCES

1. Joseph E, Hamori CA, Bergman S, et al. A prospective randomized trial of VAC vs standard therapy of chronic nonhealing wounds. *Wounds*. 2000;12:60-67.
2. Renshaw AA, Derhagopian RP, Gould EW. Cystic neutrophilic granulomatous mastitis: an underappreciated pattern strongly associated with gram-positive bacilli. *Am J Clin Pathol*. 2011;136:424-427.
3. Taylor GB, Paviour SD, Musaad S, et al. A clinicopathological review of 34 cases of inflammatory breast disease showing an association between corynebacteria infection and granulomatous mastitis. *Pathology*. 2003;35:109-119.
4. Co M, Cheng V, Wei J, et al. Idiopathic granulomatous mastitis: a 10-year study from a multicentre clinical database. *Pathology*. 2018;50:742-747.
5. Morykwas MJ, Argenta LC, Shelton-Brown EI, et al. Vacuum-assisted closure: a new method for wound control and treatment: animal studies and basic foundation. *Ann Plast Surg*. 1997;38:553-562.
6. Expert Working Group. Vacuum assisted closure: recommendations for use: a consensus document. *Int Wound J*. 2008;5(Suppl 4):iii-19.

How to cite this article: Maráz R, Venczel L, Sikorszki L, et al. Negative pressure wound therapy of Corynebacterium jeikeium associated granulomatous mastitis. *Breast J*. 2019;00:1-3. <https://doi.org/10.1111/tbj.13573>